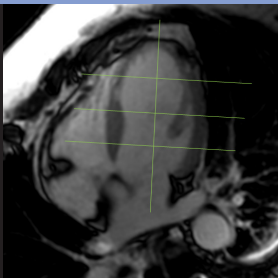




GE Optima\* MR450w

Patient with proximal LAD plaque rupture and apical anterior wall akinesia. MRI performed post cardiac event reveals wall motion and ischemic defects, as well as the presence of myocardial scar.

FIESTA Cine imaging, 2D MDE and FGRE Time Course were used to assess wall motion, viability & ischemic defect respectively.



FGRE Time Course utilizes a non-selective saturation pulse to provide uniform myocardial suppression. Multi-plane acquisition enables short axis and long axis imaging to provide assessment of the left ventricle including the apex.

# Cardiac MR in Ischemic Cardiomyopathy

## Comprehensive assessment aids differential diagnosis

**Dr Smain Sayah and  
Dr Shahin Nikkhou**  
GIE – IRM de Creil, France

“In the CAD, cardiac MRI is a reference technique for the assessment of myocardial time-course and viability, helping with therapeutic decision.”



Dr S. Sayah, MD



Dr S. Nikkhou, MD

### Patient History

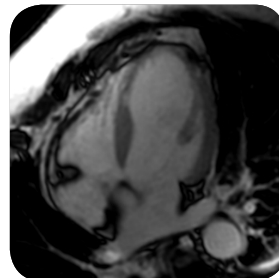
A 39-year-old man has a history of chest pain with troponin elevation dating in October 2010. Cardiac Scintigraphy normal.

The patient underwent a coronary-angiography that depicted a plaque rupture at the proximal LAD and an appearance of thrombus at the distal part.

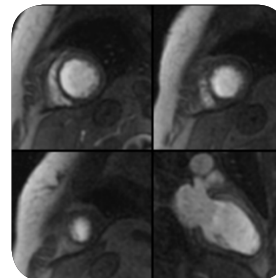
Akinesia of the anterior wall at the apical segment was seen on Echocardiography Referred to MRI in November for further exploration.

### MR Technique

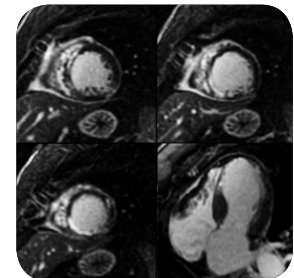
FIESTA Cine in long and contiguous short axes was performed to assess wall motion and function. FGRE Time Course (FGRE TC) with multi-plane acquisition was performed in short axis and long axis simultaneously in the same acquisition. Late enhancement ( 2D MDE) in 4 ch, long and contiguous short axes was also performed to assess viability of the myocardium.



FIESTA Cine in 4ch views of the LV shows apical, infero-septal hypokinesia



FGRE TC in multi-plane shows sub-endocardial defect at the infero-apical wall



2D MDE in short axes and 4 ch views shows a late enhancement in the myocardial scar.

### MR Findings

FIESTA Cine of the LV shows apical, infero-septal hypokinesia with ejection fraction of 38%. Dynamic time-course at rest shows a corresponding sub-endocardial defect at the infero-apical wall. MDE (estimated at 50% of the wall thickness) is also seen at the infero-septal, inferior wall at the mid segment and apical segment. No thrombus was present in the left ventricle. MRI provides a comprehensive assessment of the function, myocardial tissue viability and thrombus after the cardiac event. MRI complements the other modalities to provide a complete assessment of the patient condition and its evolution over time, and greatly improve the diagnostic confidence in coronary artery diseases.

