



Signa HD Lower-Leg Array



Peripheral Vascular MR Angiography

*By Stuart Clarkson, MR Cardiovascular Applications
Product Manager, GE Healthcare*

In the United States, over 10 million people suffer from peripheral vascular disease, including 5 percent of the population over the age of 50. Peripheral vascular disease is a condition in which the peripheral arteries are narrowed causing a decrease in the volume of blood supplying the limbs, most commonly the legs.

The major cause of Peripheral Vascular Disease is atherosclerosis.

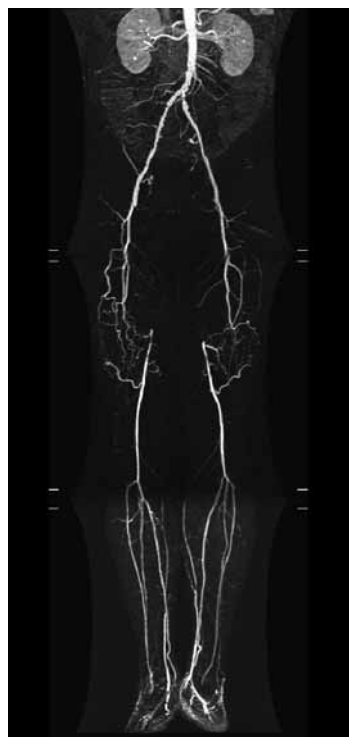Atherosclerosis comes from the Greek words athero (meaning gruel or paste) and sclerosis (hardness). It's the name of the process in which deposits of fatty substances, cholesterol, cellular waste products, calcium and other substances build up in the inner lining of an artery. This buildup is called plaque.

People with a family history of premature cardiovascular disease have an increased risk of atherosclerosis. These risk factors can't be controlled. However research¹ shows the benefits of reducing the following controllable risk factors for atherosclerosis:

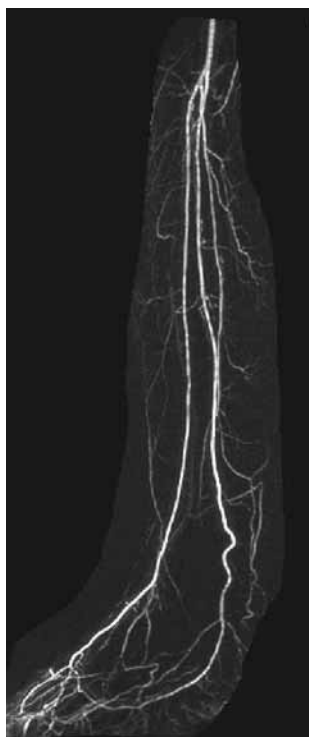- High blood cholesterol (especially LDL cholesterol over 100 mg/dL)
- Cigarette smoking and exposure to tobacco smoke
- High blood pressure
- Diabetes mellitus
- Obesity
- Physical inactivity

Current state-of-the-art MR Angiography involves a bolus chase technique of an intravenously administered Gadolinium-based contrast agent with excellent visualization of the lower limbs. However, the distal vasculature is often inadequately imaged due to signal-to-noise limitations despite the use of local phased array coils.

With the advent of higher RF channels, the technology to build a receiving coil to greatly enhance the signal-to-noise ratio (SNR) for lower limb vascular imaging now exists. A peripheral vascular (PV) coil utilizing 32 elements is proposed to increase the SNR for lower leg MRA by a factor of no greater than 12 compared to the Body T/R coil. Such a dramatic SNR improvement is expected to enable scanning at much higher resolution than currently available techniques.



Bolus chase MRA with Image Pasting



12cc Gd injection demonstrating visualization of the vessels of the lower limb.

By performing a 3D TRICKS™ (Time Resolved Imaging with Contrast Kinetics) acquisition in a sagittal scan plane, rather than the conventional coronal, the lower limb vasculature from trifurcation to dorsal pedal arch can be covered with a smaller number of slices and therefore improve temporal resolution.

By performing a sagittal scan for the vascular anatomy, a single leg may be imaged per injection. GE has developed a novel SWIFT™ (SWItch on The Fly Technique) approach to enable bilateral lower leg imaging during a single contrast injection while maintaining the sagittal 3D slice orientation for the acquisition.

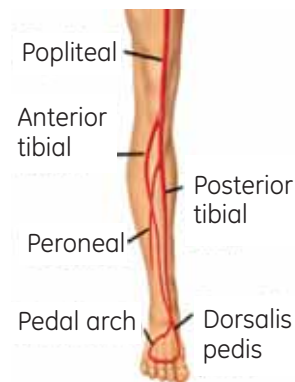
SWIFT utilizes a fast switch that enables reception of signal from either the right or left PV Coil alternately. This 'switch on the fly' technique images in conjunction with alternating TR's which excite the left leg with one TR, then the right leg with one TR and back and forward until all the phase encoding steps for both legs are completed and the images are reconstructed.

SWIFT is useful for imaging two distinct volumes simultaneously and has the added benefit of doubling the SNR due to the effective doubling of the TR for each volume. The drawback of SWIFT is the doubling of the scan time. This may be problematic with TRICKS imaging as it is desirable to maintain repetition of the 3D volume in under 10 seconds.

With the desire of performing at least 60 thin slices per leg in the 3D volumes, temporal resolution becomes the challenge with SWIFT.

To half the temporal resolution, TRICKS may be implemented with the parallel imaging technique ASSET™ (Array Spatial Sensitivity Encoding Technique), thereby easily maintaining sub 10 second temporal resolution.

As may be seen in the figure on the left, exquisite depiction of the three major vessels of the lower limb, in addition to the dorsalis pedis arch, is shown in one phase from the multiphase. TRICKS with ASSET was used at 34 seconds post IV injection of the contrast agent.



Positioning of the scan field of view in the sagittal (or oblique/sagittal) plane.

Parameter	Input
Scan Plane	Obl Sagittal
TR	6.1 ms
TE	1.7 ms
Bandwidth	42 kHz
Matrix	512 x 512
Slice thickness	1.2 mm
Number of Phases	12
Temporal Res	9 sec per phase
ASSET Factor	2 (in phase dir)

PV Study parameters of TRICKS with ASSET Scan.

Summary

SWIFT enables the use of 32 element coil technology on 32, 16 or 8 channel MR systems, ensuring all elements of the coil are scanned with a single field of view.

A novel approach to improved PV MR Angiography is proposed with high density element coils and the SWIFT 3D imaging technique. ■

Reference:

1) American Heart Association published data. <http://www.americanheart.org/presenter.jhtml>